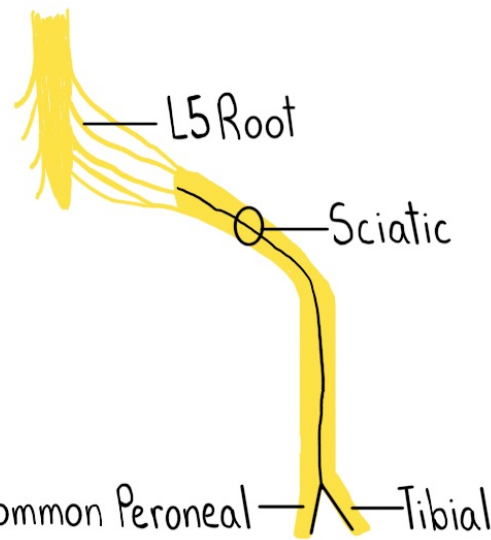


Foot Drop ^{*Dorsiflexion Weakness}

Neuroanatomy Relevant to Foot Drop

	Motor Action
L5	Inversion, Eversion, Dorsiflexion
Sciatic	PED + TIP (and Hamstrings)
Peroneal	Eversion, Dorsiflexion
Tibial	Inversion, Plantarflexion



^{*Most Common*}

Common Peroneal Neuropathy

Localize

Motor ↓

• PED

Sensory ↓

• Lateral Calf

• Dorsum of Foot

DDx

Compressive

• @Fibular Head

- Crossed Legs

- Prolonged Kneeling

• Baker's Cyst

Trauma

• @Knee

L5 Radiculopathy

Localize

Motor ↓

• LIED

• Leg Abduction

• Plantarflexion Normal

Sensory

• Pain

- Buttock, Lateral Calf

• Loss

- Lateral Calf

- Dorsum of Foot

DDx

Lumbar

• Disc Herniation

• Spondylosis

Common Peroneal — Tibial

Sciatic Neuropathy

Localize

Motor ↓

• Often PED >> TIP

• Knee Flexion

↳ Can be Affected

Sensory ↓

• Lateral Calf

• Dorsum + Plantar Foot

DDx

Compressive

• @Buttock

- Toilet seat

- Bedbound

Trauma

• Intragluteal Injection

• @Pelvis/Hip

Other

• ALS (UMN + LMN Signs)

• Strategic Brain Lesion

- Weakness Beyond Foot

- UMN Signs

• Charcot-Marie-Tooth

- Polyneuropathy

- B/I Foot Drop

• Vasculitis